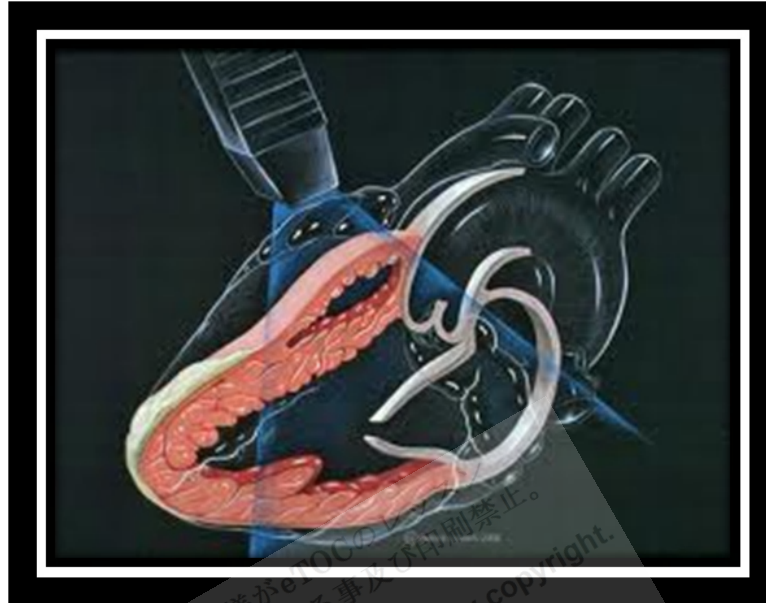

Echocardiography



http://i0.gstatic.com/images?q=tbn:ANd9GcQeVVtYEpsiMRqVHvbUu5g_KcqenWwiX6xVqxt8qllXeU6JuahplQ

Echocardiography uses ultrasound waves to produce an image of the heart and great vessels. It helps assess heart wall thickness (eg, in hypertrophy or atrophy) and motion and provides information about ischemia and **infarction**. It can be used to assess diastolic filling patterns of the left ventricle, which can help in the assessment of left ventricular hypertrophy, hypertrophic or restrictive cardiomyopathy, severe heart failure, constrictive pericarditis, and severe aortic regurgitation.

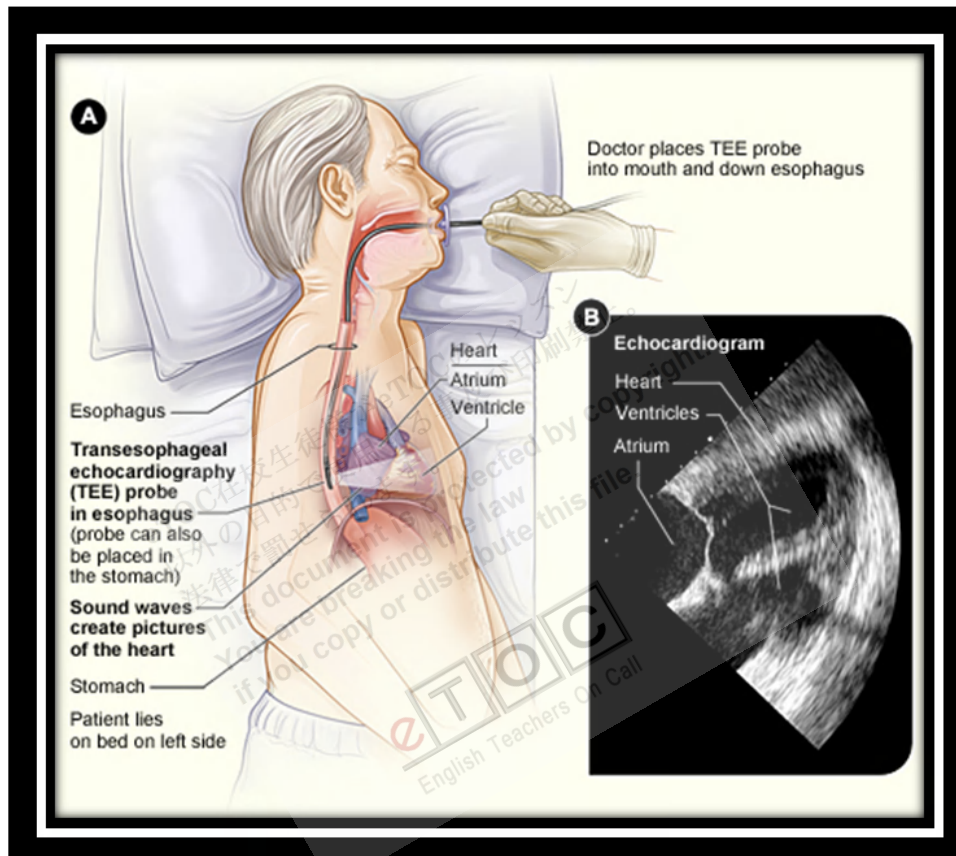
Techniques: There are 2 techniques for doing echocardiography:

- **Transthoracic**
- **Transesophageal**

In **transthoracic echocardiography** (TTE), the most common technique, a **transducer** is placed along the left or right sternal border, at the cardiac apex, at the **suprasternal notch** (to allow visualization of the aortic valve, left ventricular outflow tract, and descending aorta), or over the **subxiphoid region**. TTE provides 2- or 3-dimensional tomographic images of most major cardiac structures.

In **transesophageal echocardiography** (TEE), a transducer on the tip of an endoscope allows visualization of the heart via the stomach and esophagus. TEE is used to assess cardiac disorders when transthoracic study is technically difficult, as in obese patients and in patients with COPD. It reveals better detail of small abnormal

structures (eg, **endocarditic vegetations** or patent **foramen ovale**) and posterior cardiac structures (eg, left atrium, left atrial appendage, interatrial septum, pulmonary vein anatomy) because they are closer to the esophagus than to the anterior chest wall. TEE can also produce images of the ascending aorta, which arises behind the 3rd costal cartilage; of structures < 3 mm (eg, thrombi, vegetations); and of prosthetic valves.



http://www.nhlbi.nih.gov/health/health-topics/images/transesophageal_echo.jpg

Methodology: Two-dimensional (cross-sectional) echocardiography is most commonly used; contrast and spectral Doppler echocardiography provide additional information. Three-dimensional echocardiography is particularly useful in evaluating the mitral valve apparatus for surgical correction.

Contrast echocardiography is 2-dimensional TTE done while agitated saline is rapidly injected into the cardiac circulation. Agitated saline develops microbubbles, which produce a cloud of echoes in the right cardiac chambers and which, if a **septal defect** is present, appear on the left side of the heart. Usually, the microbubbles do not traverse the pulmonary capillary bed; however, one agent, **sonicated albumin microbubbles**, can do so and can enter left heart structures after IV injection.

Spectral Doppler echocardiography can record velocity, direction, and type of blood flow. This technique is useful for detecting abnormal blood flow (eg, due to regurgitant lesions) or velocity (eg, due to stenotic lesions). Spectral Doppler echocardiography does not provide spatial information about the size or shape of the heart or its structures.

Color Doppler echocardiography combines 2-dimensional and spectral Doppler echocardiography to provide information about the size and shape of the heart and its structures as well as the velocity of and direction of blood flow around the valves and outflow tracts. Color is used to code blood flow information; by convention, red is toward and blue away from the transducer.

Tissue Doppler imaging uses Doppler techniques to measure the velocity of myocardial tissue contraction (rather than of blood flow). These data can be used to calculate myocardial strain (percentage change in length between contraction and relaxation) and myocardial strain rate (rate of change in length). Strain and strain rate measurements can help assess systolic and diastolic function and identify ischemia during stress testing.

Three-dimensional echocardiography incorporates M-mode echocardiography, Doppler flow measurement, and Doppler tissue imaging to give a real-time, 3dimensional display of cardiac anatomy and function. This technique continues to evolve; its widespread acceptance and use have been **hindered** by lack of 3rd-party **reimbursement**.

Stress echocardiography: TTE is an alternative to **radionuclide imaging** to identify myocardial ischemia during and after exercise or pharmacologic stress. Stress echocardiography shows regional wall motion abnormalities that result from an imbalance in blood flow in **epicardial coronary vessels** during stress. Computer programs can provide side-by-side assessment of ventricular contraction during systole and diastole at rest and under stress. Exercise and pharmacologic protocols are the same as those used in radionuclide stress testing. Stress echocardiography is valuable in evaluating the hemodynamic severity of aortic valve stenosis in patients with significant symptoms but whose resting **transvalvular pressure gradient** is not markedly high. Stress echocardiography and radionuclide stress testing detect ischemia equally well. The choice between tests is often based on availability, the provider's experience, and cost.

Reference: <http://www.merckmanuals.com>